



## Patellar dislocation and lesions of the patella tendon

John King

*Br. J. Sports Med.* 2000;34:467-470  
doi:10.1136/bjism.34.6.467-a

---

Updated information and services can be found at:  
<http://bjsm.bmjournals.com/cgi/content/full/34/6/467-a>

---

*These include:*

### References

This article cites 24 articles, 8 of which can be accessed free at:  
<http://bjsm.bmjournals.com/cgi/content/full/34/6/467-a#BIBL>

### Rapid responses

You can respond to this article at:  
<http://bjsm.bmjournals.com/cgi/eletter-submit/34/6/467-a>

### Email alerting service

Receive free email alerts when new articles cite this article - sign up in the box at the top right corner of the article

---

### Topic collections

Articles on similar topics can be found in the following collections  
[Sports Medicine](#) (1034 articles)

---

### Notes

---

To order reprints of this article go to:  
<http://www.bmjournals.com/cgi/reprintform>

To subscribe to *British Journal of Sports Medicine* go to:  
<http://www.bmjournals.com/subscriptions/>

## Injuries of the sporting knee

Series editors: Jonathan Webb, Ian Corry

This article is the third in the series. It is written by John King who is a Senior Lecturer and Consultant Orthopaedic Surgeon at the Royal London Hospital. He has been active for many years in BASEM management and in postgraduate sports medicine education. His special interest is knee surgery and he has published several papers on the subject of jumper's knee and other lesions of the patellar tendon. This review is in two sections covering patellar dislocation and patellar tendinopathy. Anterior knee pain and patellar fractures were not part of the author's brief for the article, while lesions of articular cartilage are to be included in the next paper in the series.

There is current interest in the medial patellofemoral ligament and the potential for its reconstruction as a major restraint in preventing lateral displacement.<sup>1</sup> This will become a topical consideration alongside the techniques described in the review. The role of the impinging lower pole of the patella in patellar tendinosis is another topical subject under consideration and mentioned in the review. Such concepts appeal to the orthopaedic surgeon because they give mechanical clues to the cause and, by implication, the surgical treatment in these conditions. In practice, the treatments should always be conservative if possible; however, functional deficiency, implying functional rehabilitation as treatment, is much more difficult to quantify. Until our evidence base for treatment is more than just empirical, there is an important message in the article urging treatment of the patient rather than the imaging appearance.

Consultant Orthopaedic Surgeon  
Royal Victoria Hospital, Belfast, N Ireland

I CORRY

Consultant Orthopaedic Surgeon  
Southmead Hospital, Bristol, UK

J WEBB

1 Nomura E, Horiuchi Y, Kihara M. Medial patellofemoral ligament restraint in lateral patellar translation and reconstruction. *Knee* 2000;7:121-7.

## Patellar dislocation and lesions of the patella tendon

### Patellar dislocation

This paper looks at patellar dislocation only in the sports injury context. It does not refer to congenital and habitual dislocation.

Dislocation is simply divided into two groups, acute and recurrent (fig 1). Recurrent dislocation is a consequence of abnormal anatomy, either secondary to previous trauma or from the basic structure of the knee.

#### PRIMARY ACUTE DISLOCATION

This type of dislocation is caused by a high energy transfer. This implies that a lot of force was needed to displace the patella. This may take the form of a tangential blow across the front of the knee or may be a very violent twisting flexing movement.

The diagnosis is usually clear from the history. Examination may disclose the patella still lying lateral to the joint, but more usually the dislocation has been reduced and there is a swollen knee with a tender line parallel to the medial border of the patella reflecting the retinacular tear.

It is important to realise that the anatomy was normal before injury and therefore treatment should be directed at restoring this normality. If the patella lies normally centred in the femoral groove and there is no separated fragment of bone from the patella (medial edge or apex of the ridge) or the lateral femoral condyle, conservative treatment is appropriate. This should take the form of initial aspiration to relieve the pressure within the joint, followed by some form of immobilisation. My preferred treatment is to apply a brace to restrict flexion to a few degrees at first and then, after two to three weeks, to gradually increase the amount of bending. Healing tissue must be subjected to some strain so that it heals with collagen that does not subsequently stretch.<sup>1</sup>

On computed tomography (CT) scan, the patella should be lying centrally in the groove. Fractures are generally too small to fix and should be removed arthroscopically. If the patella is not central, the medial structures need repair.

#### RECURRENT DISLOCATION

This is a low energy transfer phenomenon. It takes little force to dislocate the patella, and often a trivial twisting flexion movement with the foot going into external rotation is enough.

If the recurrent dislocation follows an initial high energy transfer injury, the anatomy was previously normal. Conservative treatment by strengthening the medial structures should be tried, but surgery is often necessary. The object is to replace the patella in a central position. Medial repair and reefing are essential, and usually lateral release is needed as the lateral structures have shortened. It is essential not to medialise the patella excessively as secondary problems can then occur.

Greater difficulty arises when the initiating injury is of low energy. This implies that the anatomy of the patella femoral joint was abnormal. Estimation of the abnormality may be difficult and its correction even more so. Unfortunately, meniscectomy is still sometimes performed when the diagnosis is not made correctly.

The anatomical abnormality should be assessed at three levels.

#### (1) Proximal malalignment

This is the situation in which there is excessive femoral inward rotation so that the patella is thrust medially, but there are strong lateralising forces from the insertion of the patella tendon on the outer aspect of the proximal tibia.

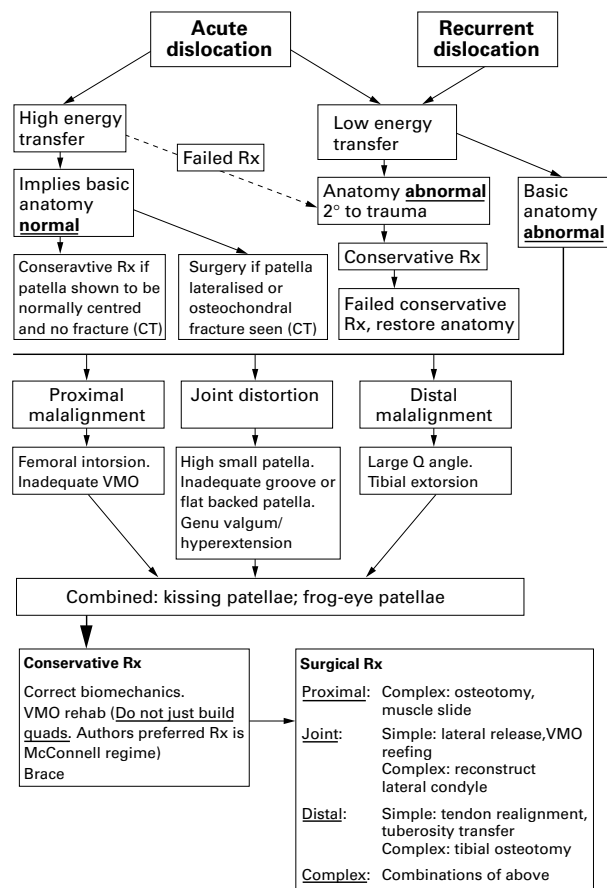


Figure 1 Patellar dislocation. Rx, treatment; VMO, vastus medialis obliquus muscle; CT, computed tomography.

This is often compounded by inadequate superomedial structures, particularly the vastus medialis obliquus muscle (VMO).

**Investigation:** It is always difficult to assess the rotation in a long bone. CT cuts at the neck shaft junction and the centre of the trochlear groove may use a high radiation dose. The future may lie in high resolution ultrasound scanning, or magnetic resonance imaging (MRI) as the cost comes down and availability increases.

**Treatment:** Conservative treatment must be tried and takes the form of trying to build up the VMO plus correction of tibial rotation with orthotics (although the tibial intorsion that is coupled with foot pronation may be helpful). Surgery is complex and involves either a rotatory femoral osteotomy or a major muscle slide moving the extensor muscles medially. The femoral osteotomy would normally be associated with a tibial osteotomy and this is too much surgery for the average patient. Fortunately recurrent dislocation simply due to proximal malalignment is very rare.

### (2) Joint distortion

The small high patella (patella alta) is a major cause. As the knee flexes, the patella does not engage properly in the femoral groove and may slip down the outer side rather than the main channel. This is quite easy to spot clinically because the kneecap feels smaller and higher than usual! It is very useful to watch the dynamics of knee flexion: the patella starts off a little lateral, and, when it engages the femoral groove, an obvious medial jump is visible. Although the small high patella is described as a separate entity, it is often associated with other abnormalities. The actual shape of the femoral groove varies and there may be

a very inadequate lateral wall. The back of the patella may be flatter than normal and both of these may cause the patella to slip around like a puck on an ice rink. Any lateralising force is likely to cause dislocation. Genu valgum may add to these problems along with hyperextension, which lifts the patella away from its groove.

**Investigation:** Various authors have described ratios to determine the height of the patella.<sup>2,3</sup> The problem relates always to the tension in the tendon and these films are at best an adjunct to the clinical diagnosis. There are also descriptions and classifications of patellofemoral congruence.<sup>2,4</sup> These are also a useful adjunct. Unfortunately, there is a tendency to treat the imaging appearance rather than the patient. The investigations are there to help with the clinical diagnosis, not to make it.

**Treatment:** At this level, re-education of the VMO may offer the best hope. A simple "quadiceps drill" is guaranteed to make the situation worse. The actual tracking of the patella needs to be changed, and my preferred technique is that of McConnell<sup>5</sup>, which may involve biofeedback and takes a long time. The indication for surgery is failed conservative treatment. Operations at this level are often unsatisfactory, as evidenced by the number that have been described. Lateral release and VMO reefing are described as simple procedures.<sup>6</sup> They are not hard to perform, but it is very difficult to balance the "slippery puck on its ice" and there is the risk of producing medial subluxation. As the original anatomy has never been normal, the results of this "simple" surgery are not nearly as good as in the "previously normal" group; the various loops and slings described<sup>7</sup> make medial displacement a real possibility.

Some surgeons like to distalise the patella. There is a certain logic in this, as the patella may be brought to lie in its groove; however, new contact areas are introduced. This can produce significant pain as an area of cartilage not previously in contact with another surface becomes exposed to the very considerable patellofemoral loads.

Operations have been described to rebuild the lateral wall of the femoral groove.<sup>8</sup> I have no personal experience of doing this and I would doubt my ability to re-create a curved structure of this nature. The results are short term and inconclusive.

### (3) Distal malalignment

This takes place in the patella tendon insertion and in the shape of the proximal tibia. The line of the extensor apparatus goes from the anterior superior iliac spine to the mid-point of the patella. As that line is projected down the leg, the tibial tuberosity lies to its outer side. The amount of lateral offset is described as the Q angle, which is the angle between the line of the extensor apparatus and the line of the patellar tendon. Genu valgum increases the effect of this, which explains why recurrent dislocation is more common in girls. Because of the wider pelvis, they have a physiologically increased Q angle. External tibial torsion also carries the tibial tuberosity laterally.

**Investigation:** The naked eye is the best tool, used in conjunction with the history. An unpublished study performed by the author, in which experienced school doctors used parallel rulers to measure the tibial tuberosity offset, simply showed an unacceptable level of intra- and inter-observer variation.

**Treatment:** In surgical terms, tendon realignment and tuberosity transfer are described as simple (after failure of conservative treatment). Patella tendon realignment is usually performed in the immature patient where operations on the tibial tuberosity carry a risk of premature closure of the proximal tibial epiphysis and a secondary hyperextension deformity. The operation consists of taking the lateral half of the patella tendon off its tibial attachment

and swinging it behind and medial to the medial half thus medialising the force on the patella. It is called the Roux-Goldthwaite procedure. It may be useful in young patients. Its main risk is tendon rupture.

Tibial tuberosity transfer takes two basic forms. The first involves elevating the whole tuberosity and transposing it medially and usually distally. This distalisation carries a risk of anterior knee pain. The alternative is simple medialisation without moving the tuberosity distally. The operation is usually described as the Elmslie-Trillat procedure. The tuberosity is elevated as a strip, with the distal part remaining attached to the tibia. The distal part is simply snapped with the periosteum intact, creating a hinge upon which the proximal part is moved medially. There is no distal movement of significance and the classic operation is performed with a slight tilt in the vertical osteotomy so that there is a small amount of anterior translation. This is designed to reduce the risk of anterior knee pain.

Often more than one of these procedures is necessary with some procedure at the level of the joint combined with distal realignment. Fortunately the far more complex procedure of a proximal tibial derotation osteotomy is not often needed.

#### Combinations of levels

During observation of the knee, there are two configurations that alert the examiner to a high risk of patella dislocation. The first is the so called kissing patellae in which the kneecaps look towards each other in stance. There is femoral intorsion and tibial extorsion and usually hyperextension occurring mainly in females at risk. The second is the so called frog eye patellae where, in flexion, the kneecaps sit high and look outwards like the eyes of a frog. Both of these indicate combinations of levels of malalignment.

This article does not address the issue of generalised hypermobility as a cause of patella dislocation although it is obviously associated in some cases.

#### Patellar "tendinitis"

Patellar tendinopathy is now the common term for patellar tendon pain in athletes engaged in running and jumping activities.<sup>3 9-12</sup> It is useful to think of it as tendinitis, an inflammation of the structures surrounding the tendon, and tendinosis, a degenerative lesion of the body of the tendon. The term "jumper's knee"<sup>9,13</sup> probably contains too many diagnoses to be useful today.

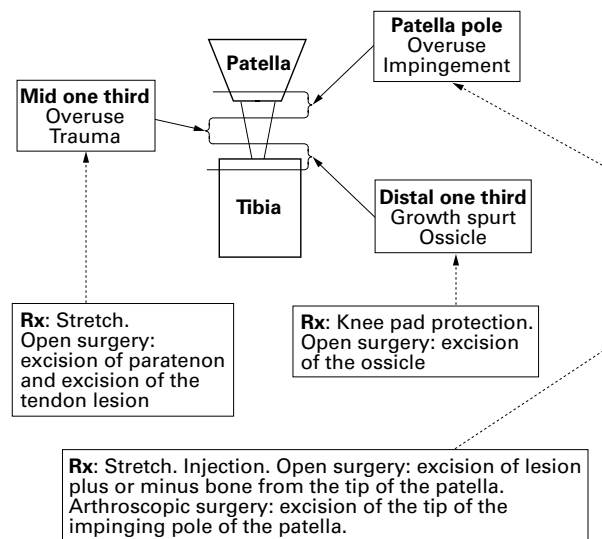


Figure 2 Lesions of the patella tendon. Rx, Treatment.

Tendinitis is characterised by patellar tendon discomfort on activity. The pain is worse going downstairs and the patient is unable to sit with the knee bent for long periods (named "the cinema sign" by the French). There may well be a sensation of insecurity. On examination, the tendon may be tender to palpation over its whole length. More usually it is localised to the lower pole of the patella. This tenderness is often worse when the knee is flexed, as the tendon is stretched and the tight tendon becomes the anvil for the hammer of the palpating finger.

It is important to realise that there is an overlap of symptoms with those from the patellofemoral joint.

Tendinosis has a similar set of symptoms but the tenderness seems to be less when the tendon is under tension in full flexion, perhaps because the area of deep degeneration is "protected" from palpation by the tight superficial fibres. Tendinosis has many causes, probably the result of prolonged repetitive mechanical stresses.<sup>13-15</sup> The rectus femoris crosses the hip, and the commonest "chronic tendon" problems are in situations where the musculotendinous unit crosses two joints: patellar tendon, Achilles tendon, biceps tendon, and medial and lateral epicondylitis at the elbow. The initial intratendinous changes are usually the product of microtears leading to localised collagen degeneration and subsequent mucoid degeneration or fibrosis. Sometimes there are genuine cysts, and vascular infiltration is very common.<sup>12 16</sup>

The affected areas are best divided into three (fig 2).

#### (1) THE PATELLA POLE

The classic jumper's knee occurs mainly at the bone-tendon junction at the inferior pole of the patella.<sup>4 10 13 16 17</sup> There is rarely a history of acute trauma. The complaint is of gradual onset of pain on stressing the tendon. The pain is well localised to the tip of the patella. It may be necessary to palpate under the tip to find the tenderness. The classic cause is microtearing at this site. Recently an impingement syndrome from a prominent patellar pole has been hypothesised in some of these cases.<sup>18</sup> Very rarely in the immature skeleton, there is a direct overuse phenomenon, as seen in board divers who exit the pool via the side rather than the steps, pressing this area on the poolside as they do so.

#### Investigation

For the isolated lower pole lesion, some idea of its size and position is essential. MRI, ultrasound, and CT scanning are all useful, and the choice depends on what is available, how well the clinician can interpret the data, and the interaction between the radiologist and the clinician.

#### Treatment

Treatment at this level depends on the nature of the lesion. In the "diver's knee" the only hope is education; injections and surgery have not been successful. In the small localised lesion, injection of steroid into the damaged area may be effective<sup>19</sup> if followed by two to three days of rest and then a full stretch programme particularly of the rectus femoris. It crosses both the hip and knee, and full hip extension is often neglected. It has been shown that it is almost impossible to introduce steroid or any other injectable substance into normal tendon because the pressure needed is too great; however, it is easier to inject into degenerative tissue (Lee S, Dissertation for Diploma in Sports Medicine).

When on CT the lesion is much over 6 mm across, this may not be effective and the athlete either lives with the lesion or has surgery. In the more extensive lesion, open surgery is necessary, with stripping of the paratenon and then division of the tendon itself in the line of the fibres, with complete removal of all macroscopically abnormal tissue. If the tip of the patella is included in the lesion, it is

best excised. Johnson<sup>18</sup> has described a more localised lesion, where a prominent tip of the patella impinges on the tendon; he quotes 90% good or excellent results (one to four years) in 35 cases in which the tip of the patella was excised using an arthroscope.

### (2) THE MIDDLE THIRD

In the middle third, tendinopathy of the main body of the patellar tendon has only recently been identified as a distinct entity, with a different prognosis and management plan from "classical" jumper's knee.<sup>12 20 21</sup>

The physical signs are tenderness in the mid-part of the tendon. A very useful sign is the diminution of local tenderness as the tendon is put under tension by flexing the knee fully. This has been described as the London Hospital sign.

### Investigation

Ultrasonography, CT scanning, and MRI are all highly sensitive and specific in localising intratendinous lesions.<sup>12 16 22-</sup>

<sup>24</sup> They can show the dimensions of the patient's tendons, and record the presence or absence of hypoechoic or hyperechoic regions, dishomogeneity, hypotense or hypertense regions, and tendon calcification. A discrete area of intratendinous dishomogeneity is interpreted as a degeneration focus. Such an area has been identified in 37 out of 45 patients with symptoms; in eight patients the whole tendon appeared to be thickened.<sup>12</sup> The area of tenderness was often located in the main body of the tendon, some 2 cm distal to the lower pole of the patella.

### Treatment

In spite of physiotherapy, local injection, and stretching, this form of patellar tendinopathy often becomes chronic.<sup>13 25 26</sup>

Once the conservative approach has failed, surgical treatment is necessary. The paratenon is stripped and the tendon palpated to locate the lesion, usually evident as a discrete area of intratendinous thickening. The lesion is exposed through a longitudinal tenotomy and the macroscopically abnormal tissue excised. When the whole tendon is thickened, multiple longitudinal tenotomies are performed. No attempt is made to repair the tendon and the skin is closed over a small drain. Stretching starts when the skin is healed, and strengthening is delayed until the knee can be fully flexed with the hip in maximum extension. Return to sport is allowed once strength is 95% of that of the normal side.

The main complication is altered sensation at the front of the knee which can be a problem on kneeling. More than 90% can be expected to return to high quality sport.<sup>17</sup>

Recently, ultrasound guided percutaneous longitudinal tenotomy has been used as a minimally invasive management of patellar tendinopathy without paratenon involvement. The results have been encouraging.<sup>21</sup> This should be reserved only for this selected group of patients, as it cannot solve the problems of paratenon involvement.

### (3) THE DISTAL POLE

In the young patient, Osgood-Schlatter's disease is well recognised. It is a painful swelling of the tibial tuberosity which may be fragmented radiologically. Similar localised pain and tenderness can occur without radiological change. The symptoms are more common during growth spurts. A very small proportion carry symptoms into adult life, usually because of a separate ossicle of bone which is protuberant or even forms a false joint with the front of the tibia.

### Investigation

Although the clinical diagnosis is obvious, radiographs should be obtained. When there is a painful lump in a child, it is important to be able to reassure the parents.

### Treatment

Treatment in the young is simple pain relief. There is no need to immobilise in any way, and a neoprene sleeve offers adequate protection against the inevitable knocks. In the adult condition, local injection may help but surgical excision is the usual outcome, again with some risk of a troublesome scar.

JOHN KING

*The Royal London Hospital, London, UK*

*Director, Academic Department of Sports Medicine, School of Medicine and Dentistry, Queen Mary and Westfield College, London, UK*  
*john.king20@virgin.net*

- Chan B, Chan KM, Maffulli N, *et al.* Effect of basic fibroblast growth factor. An *in vitro* study of tendon healing. *Clin Orthop* 1997;342:239-47.
- Blackburne JS, Peel TE. A new method of measuring patellar height. *J Bone Joint Surg [Br]* 1977;59:241-2.
- Insall J, Salvati E. Patella position in the normal knee joint. *Radiology* 1971;101:101-4.
- Martens M, Wouters P, Burssens A, *et al.* Patellar tendinitis: pathology and results of treatment. *Acta Orthop Scand* 1984;53:445-51.
- McConnell J. The management of chondromalacia patella: a long term solution. *Australian Journal of Physiotherapy* 1986;32:215-23.
- Orava S, Osterback L, Hurme M. Surgical treatment of patellar tendon strain in athletes. *Br J Sports Med* 1986;20:167-9.
- Baker RH, Carroll N, Dewar FP, *et al.* The semitendinosus tenodesis for recurrent dislocation of the patella. *J Bone Joint Surg [Br]* 1972;54:103-9.
- Dupont J. Trochlea development. *Symposium of the International Society of Arthroscopy, Knee Surgery and Orthopaedic Sports Medicine*, 1999.
- Blazina ME, Kerlan RK, Jobe FW, *et al.* Jumper's knee. *Orthop Clin North Am* 1973;4:665-78.
- Khan KM, Bonar F, Desmond PM, *et al.* Patellar tendinosis (jumper's knee): findings at histopathologic examination, US, and MR imaging. *Victorian Institute of Sport Tendon Study Group. Radiology* 1996;200:821-7.
- Khan KM, Maffulli N, Cook JL, *et al.* Patellar tendinopathy: some aspects of basic science and clinical management. *Br J Sports Med* 1998;32:346-55.
- King JB, Perry DJ, Mourad K, *et al.* Lesions of the patella ligament. *J Bone Joint Surg [Br]* 1990;72:46-8.
- Ferretti A, Ippolito E, Mariani P, *et al.* Jumper's knee. *Am J Sports Med* 1983;2:58-62.
- Renstrom P, Johnson RJ. Overuse injuries in sport. A review. *Sports Med* 1985;2:316-22.
- Walter SD, Sutton JR, McIntosh JM. The aetiology of sports injuries. A review of methodologies. *Sports Med* 1985;2:47-56.
- Myllymaki T, Bondestam S, Suramo I. Ultrasonography of the jumper's knee. *Acta Radiol* 1990;31:147-9.
- Leo R, Schonhuber H, Costa G, *et al.* A biomechanical approach to the cause and origin of patellar enthesitis in skiers. *Journal of Sports Traumatology and Related Research* 1993;15:171-8.
- Johnson DP. Arthroscopic surgery for patellar tendinitis: a new technique. *Arthroscopy* 1998;14(suppl 1):44.
- DaCruz DJ, Geeson M, Allen MJ, *et al.* Achilles paratendinitis: an evaluation of steroid injection. *Br J Sports Med* 1988;22:64-5.
- Scranton P, Farrar E. Mucoid degeneration of the patella ligament in athletes. *J Bone Joint Surg [Am]* 1992;74:435-7.
- Testa V, Capasso G, Maffulli N, *et al.* Ultrasound guided percutaneous longitudinal tenotomy for the management of patellar tendinopathy. *Med Sci Sports Exerc* 2000;in press.
- Bodne D, Quinn SF, Murray WT, *et al.* Magnetic resonance images of the chronic patella tendonitis. *Skeletal Radiol* 1988;17:24-8.
- Cook JL, Khan KM, Harcourt PR, *et al.* A cross sectional study of 100 athletes with jumper's knee managed conservatively and surgically. The Victorian Institute of Sport Tendon Study Group. *Br J Sports Med* 1997;31:332-6.
- Maffulli N, Regine R, Carrillo F, *et al.* Ultrasound scan in knee pain in athletes. *Br J Sports Med* 1992;26:93-6.
- Colosimo A, Bassett F. Jumper's knee. *Orthop Rev* 1990;19:58-62.
- Kelly DW, Carter VS, Jobe FW, *et al.* Patella and quadriceps tendon ruptures: jumper's knee. *Am J Sports Med* 1983;12:375-80.

### Further reading

- Fritschy D, De Gautard R. Jumper's knee and ultrasonography. *Am J Sports Med* 1984;12:375-80.
- Khan KM, Maffulli N. Tendinopathy: an Achilles' heel for athletes and clinicians. *Clin J Sports Med* 1998;8:151-4.
- Karlsson J, Lundin O, Lossing IW, *et al.* Partial ruptures of the patella ligament: results after surgical treatment. *Am J Sports Med* 1992;20:390-5.
- Maffulli N, Binfield PM, Leach WJ, *et al.* Surgical management of tendinopathy of the main body of the patellar tendon in athletes. *Clin J Sport Med* 1999;9:58-62.
- Maffulli N, Testa V, Capasso G, *et al.* Results of percutaneous longitudinal tenotomy in Achilles tendinopathy in middle- and long-distance runners. *Am J Sports Med* 1997;25:835-40.
- Merchant AC, Mercer RL, Jacobsen RH, *et al.* Roentgenographic analysis of patellofemoral congruence. *J Bone Joint Surg [Am]* 1974;56:1391-6.
- Mourad K, King J, Guggiana P. Computed tomography and ultrasound imaging of jumper's knee-patellar tendinitis. *Clin Radiol* 1988;39:162-5.
- Nichols CE. Patellar tendon injuries. *Clin Sports Med* 1992;11:807-13.
- Panni AS, Tartarone M, Torto MD, *et al.* Results of lateral retinacular release after 5-12 years. *Symposium of the International Society of Arthroscopy, Knee Surgery and Orthopaedic Sports Medicine*, 1999.
- Roels J, Martens M, Mulier JC. Patellar tendinitis (jumper's knee). *Am J Sports Med* 1978;6:340-3.